Virginia Commonwealth University
Transportation Safety Training Center
Virginia Multi-disciplinary Crash Investigation Team

Report Number 211– June, 2010

ABSTRACT

A Sport Utility Vehicle (SUV) travelling on a two lane primary road drifted into the opposing lane of traffic. It collided head-on with a car that was just rounding a curve, killing four of the five occupants. The SUV driver and surviving car passenger both suffered serious injuries and both vehicles were totaled.

This crash illustrates the dangers of driving while fatigued, under the influence of alcohol and drugs, and/or otherwise impaired, as well as problems associated with collisions between vehicles of differing sizes. The life saving potential of airbags and seat belt use is discussed, as well as their limitations. In addition, roadway geometry and its role in perception are considered.

Virginia Commonwealth University

Transportation Safety Training Center

Virginia Multi-disciplinary Crash Investigation Team

Report Number 211 – June, 2010

SYNOPSIS

Day, Time, Season: Sunday, 2:52 a.m., Spring

Road/Weather: Primary highway, dry and clear

Vehicles Involved: 2002 Chevrolet Tahoe Sport Utility Vehicle (SUV)
2004 Toyota Corolla four door sedan

Summary: The Tahoe drifted into the opposing lane of travel and struck the Corolla head-on.

Severity: Four fatalities, two people seriously injured, extensive property damage

Probable Cause: Fatigued, inattentive driver drifted into oncoming travel lane while entering a curve.

Significant Points: Driving while fatigued, under the influence of alcohol and drugs, and/or otherwise impaired; larger versus smaller vehicles in collisions; driver perceptions of other vehicles' position in curves.

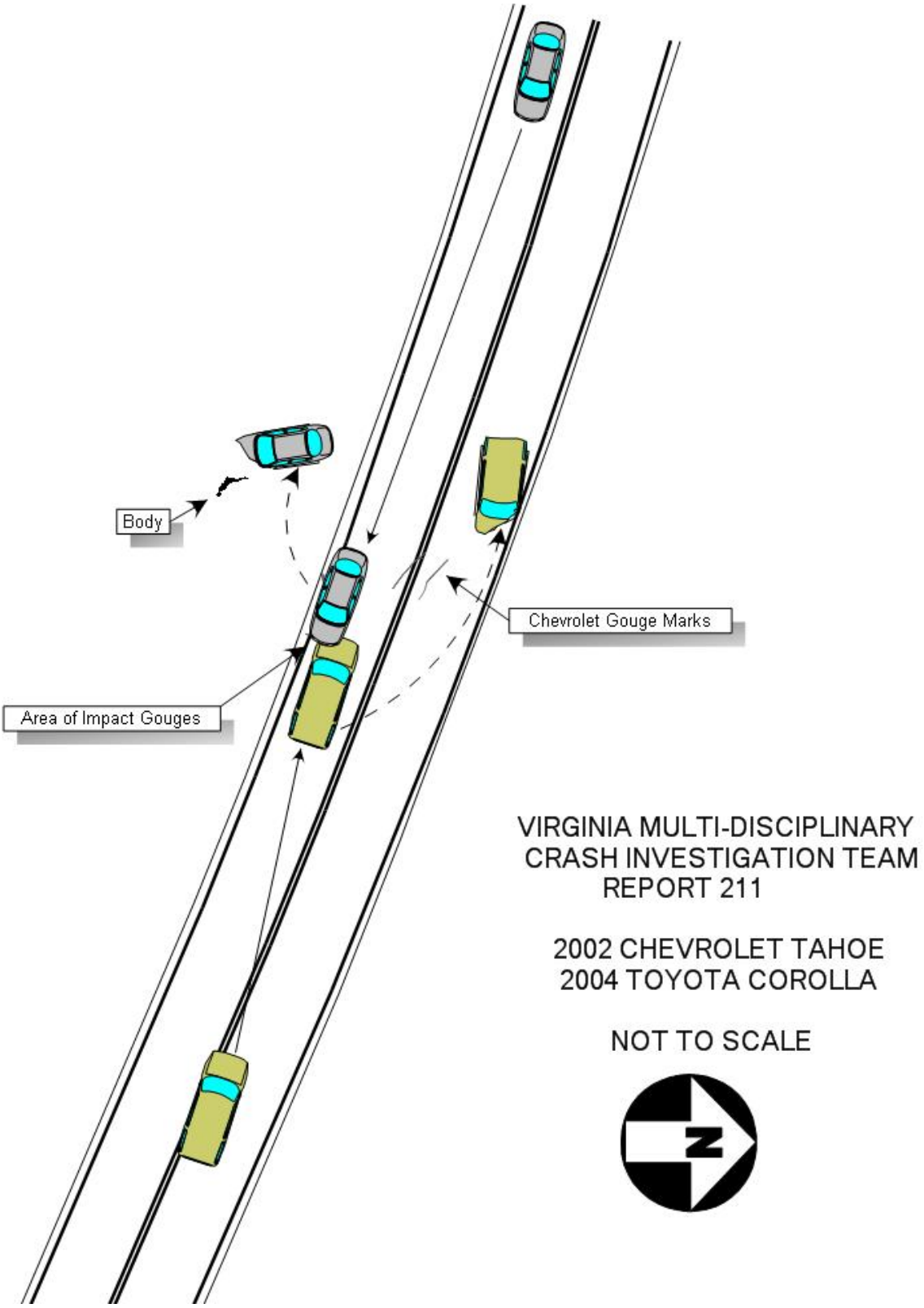

Diagram – Vehicle Movement

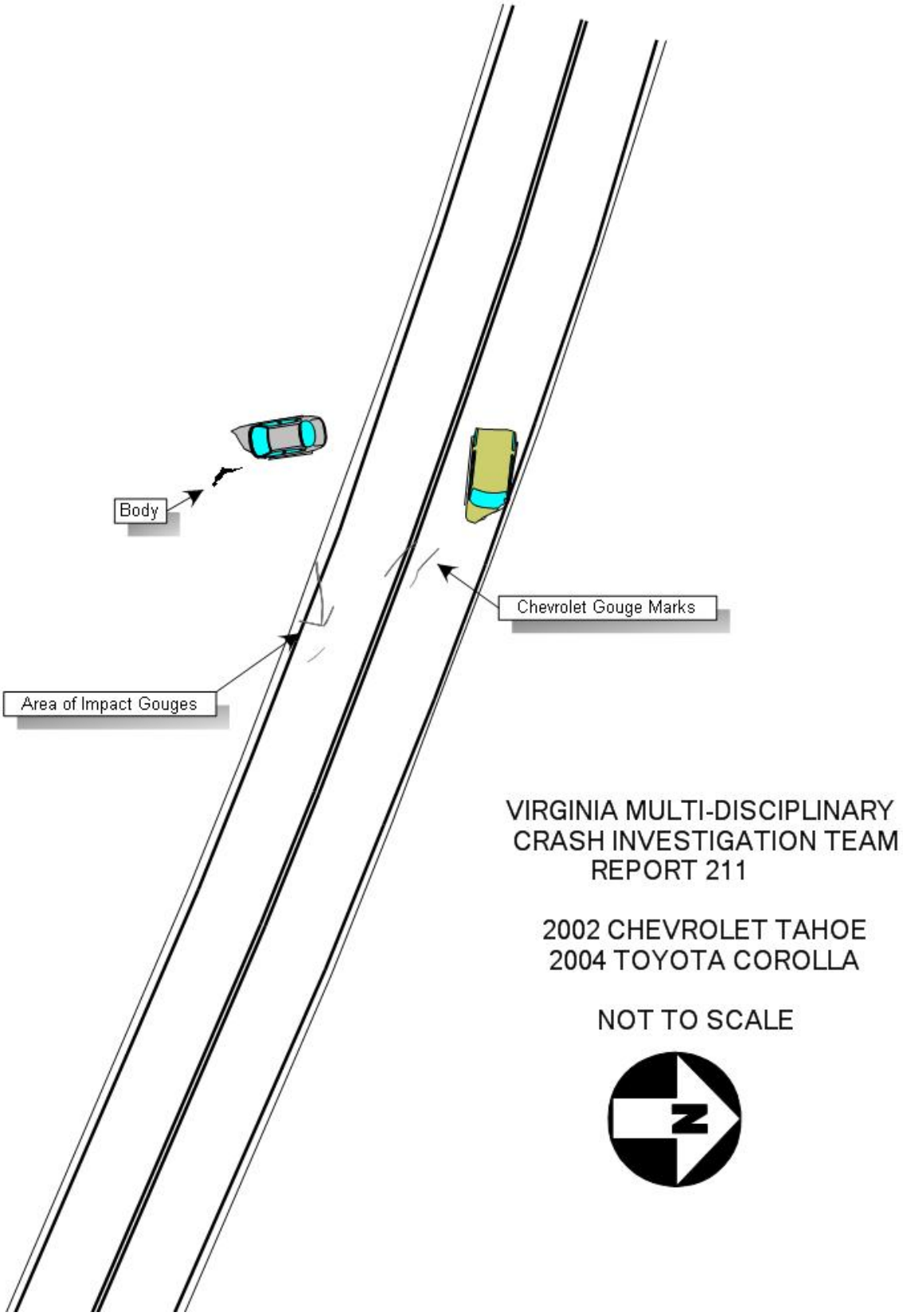

Diagram – Final Rest

CRASH DESCRIPTION

At 2:52 a.m. on a cool, clear Sunday morning, a silver/gray 2004 Toyota Corolla was travelling east along a primary highway, approaching a long arching curve to the right. The 20 year old male driver was accompanied by four friends. A 20 year old male sat in the right front passenger seat, wearing a lap/shoulder belt. Behind him sat an unbelted 27 year old male. He was accompanied in the center seat by his girlfriend, who was 20, and unbelted. A 21 year old male sat behind the driver, also unbelted. The earlier activities of the five young adults are unknown.

The road is a major two lane east-west primary route located in a rural area. Each lane is approximately 11 feet wide. The pavement is in good condition. There is an 11 foot gravel shoulder adjacent to the westbound lane and a 6 foot gravel shoulder adjacent to the eastbound lane.

Photo #1: View facing west, direction Chevrolet Tahoe was travelling. Impact occurred at beginning of curve.

Grass borders both gravel shoulders, which slope to drainage ditches. The road is level and curves slightly to the right in the eastbound direction. Along the westbound shoulder, chevron alignment signs are in place to provide positive guidance to drivers. The road is controlled by signs and pavement markings which are in good condition. Traffic is separated by double solid yellow lines at the location of the crash. In addition, snow plowable reflective pavement markers are installed to help delineate the roadway at night and during inclement weather. There is no overhead lighting. The speed limit is 55 MPH.

A gold 2002 Chevrolet Tahoe Sport Utility Vehicle (SUV) was travelling west on this primary highway. The driver, a 29 year old male, was alone in his vehicle and wore his lap/shoulder restraint. He had spent the evening dining with friends and then watching a sporting event on the television at a sports bar. He had travelled approximately 28 miles from the bar and was headed home, less than 10 miles away.

The SUV drifted into the eastbound lane, continuing in the wrong lane as it entered the curve. The Toyota driver rounded the curve travelling in his correct lane. There was no evidence that either driver braked heavily or took evasive action to avoid the crash.

The Tahoe struck the Corolla in an offset head-on configuration, left front to left front. The front bumper of the Tahoe overrode the front bumper of the Corolla, forcing the Corolla downward, rearward and to the right off of the roadway, into the southern grass shoulder. The pushing of the Corolla by the Tahoe created several gouge marks on the road in the eastbound travel lane. These marks were used to determine the location of the area of impact. They were confined to a small area which measured approximately 3.7 feet wide (north/south) and approximately 3.2 feet long (east/west). This area of gouge marks was located in the eastbound lane adjacent to the white edge line. Extending out of this area of gouge marks was a single gouge mark that measured approximately 9.5 feet long. This mark extended from the area of impact toward Corolla's final rest position which was located approximately 26 feet from the area of impact and facing southeast. The driver's side rear seat passenger was ejected out of the left side rear door window as the Corolla was pushed rearward and rotated. He was found approximately 4.6 feet northeast of the front end of the Corolla.

Photo #2: Area of Impact gouge marks.

During engagement, the Tahoe rotated counter clockwise and, upon separation from the Corolla, travelled rearward, coming to rest in the westbound lane approximately 30 feet from the area of impact and facing eastbound. This aspect of the collision and rotation also created gouge marks in the roadway. The first mark attributed to the Tahoe was found in the eastbound lane near the area of impact. This mark measured 3.4 feet and extended west toward the double yellow centerline. Two gouge marks were found near the double yellow centerline pavement marking north of the area of impact and extended into the westbound lane toward the final rest of the Tahoe.

All the fatalities were the result of blunt force trauma. The Toyota driver died at the scene from trauma to his head, chest and abdomen. The belted front seat passenger died from injuries to his head and chest, as did the young woman sitting in the center rear position. Although unrestrained, she remained in the vehicle. The unbelted left rear passenger was ejected, receiving fatal head and chest injuries. The only survivor in the Toyota was seated in the right rear position, unrestrained. He suffered life threatening injuries, including head trauma, a thoracic aorta injury, broken ribs that punctured a lung, and multiple fractures to his pelvis.

Two vehicles travelling in opposite directions came upon the crash shortly after it happened. One passerby called for emergency assistance and stayed on the phone with the 911 dispatcher, providing information about the victims and their status. He attempted to extricate

the lone Toyota survivor, but was unsuccessful. He checked the status of the Tahoe driver and determined that his injuries did not appear to be life-threatening. The male passenger from the second stopped vehicle assisted with the SUV driver and also located the body of the ejected Toyota passenger while checking the area. The other man returned to the conscious Toyota passenger and remained with the young man until rescue personnel and police arrived.

Initially, medical responders attempted to resuscitate the female victim, but they were unsuccessful. She was declared dead at the scene, along with the three men who had already been identified as deceased. An emergency airlift helicopter was called to transport the sole Toyota survivor and the driver of the SUV. Both were initially taken to the closest hospital with a trauma center. The Toyota passenger was later transported to a university medical center about 50 miles away for treatment of his extensive injuries. The on duty Medical Examiner was notified and he authorized removal of the bodies to a local hospital for examination.

In total, two local rescue squads, two local fire departments, officers from the county sheriff's office and Virginia State Police responded to this crash. The roadway was closed to all traffic while emergency personnel worked to extricate the pinned victims and remained closed until the investigating trooper and the Virginia State Police Divisional Reconstruction Team members measured the scene and collected evidence. As the victims were identified, the Medical Examiner's office worked with the investigators to determine next of kin and coordinate notifications. The roadway was re-opened and the scene cleared about 6½ hours after the crash.

REMARKS

The Virginia Multi-disciplinary Crash Investigation Team (VMCIT) learned of this crash when the fatalities were listed on the Virginia State Police Daily Activity Report. Preliminary investigation revealed that some in the area had questions about the safety of the roadway, so the Team decided to investigate more fully.

The 2002 Chevrolet Tahoe had a valid Virginia State inspection sticker which was due to be renewed in approximately two months. A CARFAX Vehicle History Report revealed this vehicle had been purchased by the operator in 2006 and had one previous owner. There were no maintenance records reported after this purchase in 2006. This vehicle was equipped with a downloadable event data recorder. Manufacturer's specifications on this vehicle indicate a curb weight of 4,873 lbs. An exemplar vehicle was utilized to obtain an approximate pre-crash bumper height for this Tahoe, which is typically 20 inches from the ground level.

The Tahoe was examined by members of the VMCIT post-crash at the towing company's facility. Contact damage to the Tahoe was focused on the driver's side front. The bumper was pushed inward and under the front of the vehicle. The grill and headlight assemblies were detached and broken. The hood was pushed rearward and buckled upward, and the engine compartment was pushed rearward into the firewall area. The driver's side front quarter panel was buckled and pushed rearward into the "A" pillar. The roof of the Tahoe was buckled, as well as the floorboard of the driver's area. The driver's side front tire was deflated and pushed rearward into the "A" pillar. The rear of the Tahoe showed little to no damage. The passenger's side front quarter panel displayed buckling towards the driver's side. The passenger's side front tire was deflated. The front axle had broken. The interior of the Tahoe was examined and there was no stretching or tearing to the driver's seat belt to indicate its usage. Both driver's side and passenger's side front airbags were deployed.

The Airbag Control Module (ACM) for this Tahoe was found under the carpet below the driver's seat. This ACM was removed and later downloaded, which produced a crash data report. Analysis of this report indicated the driver was unbelted and had his cruise control set at 55 MPH prior to the crash. This analysis is consistent with the roadway and vehicle examination evidence.

The 2004 Toyota Corolla had a valid and recent Virginia State inspection sticker. A CARFAX Vehicle History Report revealed no pre-crash information regarding ownership or

Photo #3: Chevrolet Tahoe at final rest, facing east in westbound lane. The Toyota Corolla is at final rest in background.

repair of this vehicle. The Corolla was not equipped with a downloadable event data recorder, so even though both the driver's and passenger's front airbags were deployed, there was no data retrieved regarding pre-crash events. Manufacturer's specifications on this vehicle indicate a curb weight of 2,568 lbs. An exemplar vehicle was utilized to obtain an approximate pre-crash bumper height for this Corolla, which is typically 16 inches from the ground level.

The Corolla was examined by members of the VMCIT post-crash and post-extrication of the driver and front seat passenger. To extricate the fatal victims, the entire roof was removed. Examination of this vehicle was therefore limited. The interior of the Corolla was examined and it was observed that the speedometer needle was stuck in a position to read 55 MPH. The post-crash position of a speedometer needle is not an accurate or reliable indicator of impact speed and there was not enough additional evidence to confirm this as the actual pre-crash speed of the Corolla. However, it appears to be consistent with the damage sustained in this collision. Both the driver's side and passenger's side front air bags were deployed. The lap/shoulder belts for these seating positions had been cut and photos taken at the scene showed these two occupants had been wearing the restraints. There was no evidence to indicate the rear seat passengers were

wearing their seatbelts and all three lap/shoulder restraints were intact and retracted fully at the time of the examination.

Photo #4: Toyota Corolla at final rest.

Contact damage to the Corolla was focused to the front of the vehicle slightly offset to the driver's side. When the front bumper of the Tahoe overrode the Corolla's bumper, it decreased the effectiveness of the energy-absorbing structures forward of the occupant compartment. The front bumper cover, grill and headlight assemblies were all dislodged from the front of the Corolla. The front bumper was pushed downward and twisted to the left side of the vehicle. The hood was crumpled upward and rearward toward the windshield of the Corolla. The engine compartment was pushed rearward toward the passenger compartment and downward. The driver's side quarter panel was crumpled and pushed to the "A" pillar. The driver's side front tire was fully deflated from the crash. The driver's side front door was crumpled. The driver's side rear door showed evidence of crumpling towards the front of the vehicle and the window was shattered and missing. The rear of the Corolla displayed little to no

damage from this collision. The passenger side rear door displayed crumpling at the "B" pillar, while the passenger's side front door showed crumpling at the "A" pillar.

The Insurance Institute for Highway Safety (IIHS) has conducted several extensive studies on the compatibility of bumpers on passenger cars versus light trucks and vans (LTVs), including sport utility vehicles (SUVs), in motor vehicle crashes. One such study (Baker, Nolan, O'Neill & Genetos, 2008) references the current U.S. Federal Regulation (49 CFR Part 581.7) concerning passenger cars and the fact there is no current federal regulation of LTV bumper heights. The regulation requires that "car bumpers must be 16 to 20 inches off of the ground and limit the amount of damage that can be sustained in a low-speed crash." This regulation does not apply to LTVs. IIHS concluded that there is a "height mismatch" between the bumpers or front-end energy-absorbing structures in regulated passenger cars and unregulated LTVs. Collisions between these two types of vehicles tend to result in an override/underride situation, which may lead to extensive damage and injuries or death. This multiple fatality crash is an example of this type of mismatch situation. Some motor vehicle manufacturers have voluntarily added "secondary front energy-absorbing structures" on some of their LTV models to assist in height-matching passenger cars. This structure is essentially an energy-absorbing device connected to the underside of the main energy-absorbing device or bumper. However, the 2002 Chevrolet Tahoe in this case was listed as being a "light truck not meeting the height-matching criteria." Had this vehicle been equipped with a secondary energy-absorbing device, it would have allowed the Corolla and Tahoe to fully utilize all energy-absorbing safety mechanisms to reduce the severity of this crash. The IIHS has petitioned the National Highway Traffic Safety Administration (NHTSA) to require that all vehicles meet the height-matching criteria that is being voluntarily implemented by some car manufacturers on some of their model lines (Nolan, 2008).

The 20 year old Toyota driver was about 30 miles from his home when the crash occurred, and he was travelling to a location further away. Although he was licensed to drive in the Commonwealth, he had received his license only fourteen months prior to the crash. However, he had been driving since 2004, when he was issued a learner's permit. Two years later, a month before he turned 18, he surrendered his learner's permit in a court action; the charges were not specifically identified in his records. Over a month later, he applied for and received another learner's permit. In 2007, he was convicted of a learner's permit violation (three demerit points), operating an uninsured vehicle, and an offense relating to registration,

licensing or titling of a vehicle. All charges occurred at the same time. When he failed to pay the related fines within a timely manner, his license eligibility and learner's permit were suspended until January, 2008, and he was required to attend a driver improvement clinic. He completed the course in January, then applied for and was issued a driver's license at the end of January. However, he failed to file insurance information or pay the uninsured motorist fee and was notified twice of possible cancellation. In July, 2008, his license was suspended for failure to maintain insurance or comply with uninsured motorist requirements. The suspension was lifted in February, 2009, just a month prior to the crash.

According to his driver's license, this young man was five feet six inches tall and weighed 240 pounds, which is consistent with the Medical Examiner's review. A toxicology report for this driver revealed that he had consumed alcohol and marijuana within hours of the crash and was under the influence of propoxyphene as well. The Medical Examiner drew a sample of blood from the driver's right subclavian vein during his post mortem examination. He stated that he was confident the sample was not contaminated by any other bodily fluids which might have affected the toxicological analysis. The tests showed that the driver's blood alcohol content (BAC) was .14%, a level well above the .08% per se limit for driving under the influence of alcohol in Virginia. This level of intoxication is likely to result in impairment of vision and coordination, impaired memory and ability to concentrate, as well as emotional instability. Consequently, the alcohol consumption alone could have been enough to affect this young man's ability to assess and/or respond to roadway hazards while driving that night. However, he combined the alcohol with other drugs. The level of tetrahydrocannabinol (THC, the active component in marijuana) in his blood, along with the absence of THC metabolites, suggests that he had smoked marijuana just before getting behind the wheel. This drug is broken down by the body and clears the blood quickly, although traces of metabolites may be stored in body tissue, especially fatty tissue, for extended periods of time. According to a forensic toxicologist, the level of THC found in the driver's blood was .028 mg/L. In addition, a third substance, propoxyphene, is likely to have caused further impairment. The blood analysis showed that he had .09 mg/L of propoxyphene and he had .73 mg/L of norpropoxyphene (a metabolite of propoxyphene) in his system. Propoxyphene, commonly sold as prescription Darvon or Darvoset, is a pain killer that can cause drowsiness. Users are warned against combining it with alcohol because the effects of the drug can be heightened and there is greater risk of tissue damage and death. Even though the Toyota driver was not "at fault" in this crash, the

impairment resulting from his use of alcohol and drugs very likely affected his ability to judge the position and speed of the oncoming vehicle. This may well have contributed to his lack of braking or any evasive maneuver to avoid the collision that killed him and three of his passengers.

During the vehicle examination, VMCIT members noticed a can of "JOOSE" inside the car. This is a flavored alcoholic "energy drink", which will contain 9.9% to 12 % alcohol, as compared to 4% to 6% alcohol found in beer. The can of "Dragon Joose", which tastes like a grape soft drink, is 9.9% alcohol and also contains caffeine, taurine and ginseng. The additional ingredients are often promoted as supplements that improve alertness and energy levels. While the research on alcoholic energy drinks—and on combining alcohol with caffeine—is limited, the results indicate that the negative effects of alcohol on motor performance and on visual reaction time were not alleviated by the addition of caffeine or other supplements in the energy drinks (Ferreira, De Mello, Pompeia & de Souza-Formigoni, 2004; Ferreira, De Mello, Rossi & de Souza-Formigoni, 2006). Those consuming such drinks may perceive that they are alert, and they may not report experiencing the typical effects of headache, dry mouth, or impairment of motor coordination; however, their subjective perceptions are inconsistent with their measured performance. Impairment is the same for those consuming alcohol, whether or not it is combined with an energy drink or caffeine. The expectation of less impairment may actually result in drinkers making fewer efforts to compensate for their actual level of impairment (Fillmore, Roach & Rice, 2002). Applying these findings to young adults, we could expect those drinking alcoholic energy drinks like "Joose" to be less likely to see the need for staying off the highways or for assigning an alcohol-abstinent designated driver to a group that is partying.

Little is known about the pre-crash activities of the Toyota occupants. As a consequence of his head injuries, the sole survivor did not retain any memories of the crash or much of the day preceding it. His last memory prior to waking in the hospital is of standing in his living room earlier in the day, playing video games. He indicated that he had learned second hand that the group had been travelling to a rear seat passenger's home and had missed a turn. The driver had turned around to head back to their destination, about 30 miles further east. According to the survivor, the driver was probably not familiar with the area or the roadway. Toxicology reports on the deceased passengers showed that none had alcohol in their blood. No additional drug analyses were performed on the blood samples. The Team was unable to determine when the

Toyota driver joined the group, what else the group did, the length of time they spent together in the car, or if they knew the driver was impaired.

Although the driver and front seat passenger were restrained, they could not have survived this crash. Their occupant space was severely compromised as the Toyota's engine pushed against the dash and floorboards. Both were pinned in the wreckage and suffered multiple fractures to their extremities in addition to blunt force trauma to their head and chest areas. Bruising from both shoulder and the lap pathways of the belt was visible on the driver's body when the Medical Examiner performed his examination. None of the rear seat occupants wore their safety restraints. In addition to chest abrasions and contusions, the ejected passenger suffered skull fractures, most likely from striking the interior of the vehicle as he was thrown about, and then from striking the ground. These injuries may not have been as severe, much less fatal, if he had remained in the vehicle. Similarly, the female passenger would have had a higher probability of surviving if she had been restrained.

The survivor in the Toyota was critically injured in this crash and underwent several medical procedures to repair his head injury, thoracic aorta injury and broken bones. It is likely that his injuries would have been less severe had he worn his lap/shoulder belt and especially if the other rear seat passengers has also been restrained. He spent a week in the hospital and continues with rehabilitation. His doctor indicated that he should regain 90% of normal functioning, but recovery will be a long term effort.

The Tahoe driver has been licensed in the Commonwealth since 1998. According to his driving record, he had been involved in a property damage only crash in 2007 but was not convicted of any related charges. In 1999, however, he was convicted of improper control and driving with faulty brakes, resulting in a deduction of four safety points. Later that year, he was also convicted of reckless driving for speeding more than 20 miles above the limit, and he a six point demerit. In 2002, he was again convicted of reckless driving (generally) and received the same demerit against his record. Although the accident does not appear on his driving record, members of the VMCIT learned that this conviction was the result of a crash the Tahoe driver had caused when he fell asleep while driving on this same route, at a different location. He had been given the option of returning to court after a year and having the conviction rescinded if he kept a clean driving record, but he did not follow through and the reckless driving conviction remained on his record. He had not been convicted of any driving infractions after that, though,

and his driver point balance at the time of the fatal crash was a positive five points, the maximum.

This young man, who was six feet five inches in height and weighed 250 pounds according to his driver's license, was fatigued at the time of the crash. He had only slept about four hours the previous night, going to sleep after 2:00 a.m. The next day, he rose early and then helped a friend move furniture during the day, a physically taxing activity. That evening, he had dinner with friends, but he reported that he did not drink alcohol with his meal. After dinner, he went to a sports bar to watch a televised basketball game. He had one beer and had ordered at second at last call, but he stated that he did not drink it. His blood later tested negative for alcohol content. After the game, he left the bar and headed home, approximately 35 miles away. He had travelled about half that distance when he began to feel unwell, so he stopped at a convenience store and purchased some orange juice and a candy bar, which he consumed prior to resuming his trip. He travelled another 11 miles before colliding with the Toyota.

At the time of the crash, this driver was operating with only four hours of sleep in a 36 hour period or longer, and he was driving during a time that he normally slept, all factors that contribute to impaired, drowsy driving and an increased likelihood of falling asleep at the wheel. He had just traversed a long stretch of four lane divided highway, which was smooth and easy to maneuver. While these are positive design features, they can be monotonous. By putting the vehicle into cruise control mode, the driver had reduced the effort he was required to make to keep the vehicle moving, leaving steering and braking as his primary motor tasks. The lack of traffic on the highway in the early hours of the morning meant he received less visual stimulation to process. All these factors are likely, at the very least, to have induced episodes of "microsleep", very short periods of time where a driver may fall asleep and then awaken without being aware that he has dozed off. This driver's statement that he recalls little of his trip after stopping at the convenience store to just before seeing the headlights of the other vehicle, in addition the fact that he could not remember which lane he was in prior to the collision, are consistent with his falling asleep at the wheel.

Two vehicles came upon the scene shortly after the crash. The first, a westbound car, carried a couple who had been out for the evening. A female physician was driving while her front seat passenger slept. She approached the scene immediately after the crash and had to swerve onto the right shoulder to avoid striking the stopped Tahoe. Since she did not have cell phone service in the location, she drove a bit further west, then pulled onto the right shoulder and

parked to call emergency personnel. The second vehicle, which was travelling eastbound, was driven by a man who had been called into work. He reported that he was very alert and awake, having had time to have a cup of coffee and go through his normal wake-up routine before leaving his home. As he approached the curve, the driver in the parked vehicle blinked her high beam headlights to warn him of a problem ahead. He continued around the curve and came upon the crash scene. He parked his car and got out, walking around the vehicles as he called 911 on his cell phone. He stated later that a passenger in the Toyota had "spilled out". The right rear door was open and this young man had the upper ¾ of his body out of the car. He was conscious and yelling for help, but he was unable to pull himself free from the vehicle because his legs were pinned by the body of the female passenger who was lying partially on top of him. It appeared to this witness that there were three people in the back seat in addition to the driver pinned in the front seat and their injuries were very serious. He did not see the front seat passenger, who was pinned in a low position with much of his body below the top of the dash. After determining that most of the occupants of the Toyota were not alive, he attempted to assist the survivor but was unable to free him from the vehicle. He then went over to the Tahoe and checked on that driver. He could not get the door open, but the window glass had broken out, so they were able to speak. He stated that the driver was conscious and coherent and that he did not appear to be in "dire straits". The witness said he did not smell alcohol on the man's breath or in the vehicle.

The car that that had passed earlier returned to the scene and the male passenger began to assist. Between the two men, they checked the vehicle occupants again. The SUV driver asked that someone call his grandmother, who was expecting his arrival. He gave his cell phone to the second passerby, who called to tell the woman that her grandson had been in a crash but that he was alright. This passerby walked around the area after the first witness returned to the Toyota. He came upon the body of the third back seat passenger, who had been ejected, and checked him for signs of life. Shortly thereafter, the first emergency responders arrived on scene and all three witnesses stepped back from the area and waited until investigators were able to take their statements and contact information.

When members of the VMCIT examined the scene of this tragic crash, there were no obvious roadway defects. The wide, sweeping curve was marked clearly and banked in a manner appropriate to the curvature, and chevrons along the outside of the curve provided positive guidance for westbound traffic. However, State Police officers familiar with the

roadway indicated that the area had frequent crashes, including several fatal crashes, although they were often due to driver error, including travelling too fast for conditions. Despite being under the influence of alcohol and drugs, the Toyota driver had successfully negotiated the sharpest section of the curve and was transitioning through the gentler area of curvature before entering a straight section of roadway when the two vehicles collided. Although he would have been able to observe the headlights of the approaching SUV, the grade and curve make it difficult to assess the relative position of oncoming vehicles in dark conditions. The Chevrolet was travelling at 55 MPH or about 80 feet per second. The Toyota was likely travelling at a similar speed, but even if the driver had slowed to well below the speed limit, he would have had little time to assess the position of the oncoming SUV.

Photo #5: View facing east, the direction the Toyota Corolla was travelling.

This route is a main thoroughfare between several mid-sized towns and cities in an otherwise rural area of the Commonwealth. The average annual daily traffic volume is 7800 vehicles for this section of roadway (Virginia Department of Transportation, 2008). The

Virginia Department of Transportation (VDOT) conducted a safety assessment on a 4.62 mile section of roadway that includes the crash location (VDOT currently reviews all roads after every fatal crash to determine if there are ways to improve safety). The safety assessment report included some of the following key elements: inventory of existing conditions, traffic counts and speed data information, sight distance, speed limit study review, crash analysis, roadway geometrics and land use analysis, and recommendations (Short Term and Long Term solutions to enhance operations and safety), as well as an implementation plan.

Part of the safety assessment included evaluating crash experience on the roadway from the period August 1, 2005 to July 31, 2008. Fifty-seven crashes occurred on this section of road, resulting in 42 injuries and 2 fatalities. The crash types included: 7 rear end collisions, 9 angle collisions, 10 sideswipe collisions, 17 fixed object crashes, 1 head-on crash, 2 non-collision crashes, and 11 deer/animal crashes. Another crash after this reporting period resulted in a single fatality, in addition to the fatalities associated with the crash the VMCIT investigated for this report. According to the assessment, fatality rates are well above the state and district averages for this type of roadway.

Some Short Term solutions were identified to improve awareness and increase safe behaviors as drivers approached the curve. These included (1) increasing the size of the Advance Curve Warning signs, (2) installing advisory speed limit signs (50 MPH) in advance of the curve in both directions, and (3) installation of two sets of Transverse Rumble Strips. These strips would cross the entire lane on the approaches to the curve eastbound and westbound, providing a mechanical vibration to alert drivers. The faster a vehicle travelled, the greater the vibration and noise would result. To improve positive guidance through the curve, the assessment suggested (4) installation of additional W1-8 CHEVRON signs on the outside of the horizontal curve for the eastbound and westbound directions, (5) installing reflective flex posts to increase delineation, and (6) installing snow plowable pavement markers on the centerline in areas that that do not currently have them. The assessment also recommended (7) installing stop bars on the secondary roads on the approach to the primary road and adjusting some of the passing zones in order to enhance and encourage safe passing practice. The implementation of these Short Term solutions was completed six months after the crash occurred.

One Long Term solution suggested was to widen the curve section of the road with up to 6 feet of paved shoulder in each direction from a point beginning where the current paved section ends, easterly for approximately 100 feet encompassing the horizontal curve. This would

provide additional pavement width for drivers traversing the curve and allow opportunity to regain control in the event a vehicle should cross the edge line. To enhance visibility, including nighttime visibility, and to increase guidance by improving the delineation of the curve, the assessment authors recommended installing a double row of snow plowable pavement markers, replacing the existing double yellow centerline with 6 inch yellow lines and installing 6 inch edge lines on both sides of the road. Additionally, the report suggested installing centerline rumble strips to discourage drivers from hugging the centerline, thus reducing the potential for sideswipe (opposite direction) and head-on collisions. Another solution identified that the inside of the curve should be delineated with reflective flex posts from point of curve (PC) to point of tangent (PT) once the widened shoulder is in place. It recommended that these measures be implemented at the same time that pavement widening is performed, since some drivers may shy away from the centerline and will need additional pavement width to compensate for the lateral movement. These Long Term solutions were completed nine months after the crash occurred. The report also recommended that the two lane section should be upgraded with markings. VDOT is in the process of obtaining funds and programming the installation of epoxy pavement markings. Finally, the assessment noted that future capacity considerations may warrant widening of the two lane section to a four lane divided facility to match the existing four termini, based on planning and growth potential when funds become available.

As a result of this crash, a grand jury returned multiple indictments against the 29 year old Tahoe driver: four counts of involuntary manslaughter, four counts of wounding in the commission of a felony, one count of destruction of property over $1000 with intent, one count of reckless driving and one count of operating an uninsured vehicle. He was tried by jury. The prosecution stressed the fact that the Tahoe driver knew he was fatigued and therefore should not have been driving. The defendant's lawyer, in his concluding arguments, countered "We never once said this wasn't a horrible accident." However, he asked the jury to put themselves in the driver's shoes: "I want you to judge him like you'd want to be judged and find him not guilty." He argued that his client's alleged impairment did not rise to the level of criminal negligence required under the involuntary manslaughter statute he was charged with (§18.2-36). Case notes under this statute indicate that a conviction for involuntary manslaughter requires "negligence so gross, wanton and culpable as to show a reckless disregard of human life. King v. Commonwealth, 217 Va. 601, 231 S.E.2d 312 (1977)" (Virginia State Police, 2008). As a matter of law, the judge could not allow the jury to hear evidence that the Tahoe driver had been

convicted of reckless driving seven years earlier, when he fell asleep while driving and caused a crash. The jury returned “not guilty” verdicts on the manslaughter charges and convicted this young man of the reckless driving charge. He was sentenced to six months in jail with eligibility for work release and home electronic monitoring. His license was suspended for six months as well.

RECOMMENDATIONS

1. The Virginia Department of State Police and local law enforcement agencies should continue to strictly enforce statutes related to driving under the influence of alcohol and/or drugs. Members of the judiciary are encouraged to continue applying appropriate consequences in cases where individuals have violated these statutes and placed others, as well as themselves, at risk.

2. The Department of Motor Vehicles, driver's education instructors, and public safety groups should continue striving to educate the general public on the dangers of fatigued driving. The Virginia Department of State Police and local law enforcement agencies should continue to strictly enforce statutes related to driving while impaired by fatigue, and the courts are encouraged to treat these cases with the same severity as driving while impaired by alcohol and/or drugs.

3. The National Highway Traffic Safety Administration, along with insurance carriers and the Insurance Institute for Highway Safety and members of the general public, should consider ways to influence motor vehicle manufacturers to increase their use of secondary front energy-absorbing structures to reduce the severity of crashes where light trucks or vans collide with passenger cars.

REFERENCES

Baker, B.B., Nolan, J. M., O'Neill, B., & Genetos, A.P. (2008) "rash compatibility between cars and light trucks: Benefits of lowering front-end energy-absorbing structure in SUVs and pickups. *Accident Analysis and Prevention, 40,* 116-125. Accessed online at www.elsevier.com/locate/aap.

Ferreira, S. E., de Mello, M. T, Pompeia, S., & Sourza-Formigoni, M.L., (2006). Effects of energy drink ingestion on alcohol intoxication. *Alcoholism: Clinical and Experimental Research, 30,* 598–605.

Ferreira, S.E., de Mello, M.T., Rossi, M.V., & Sourza-Formigoni, M.L. (2006). Does an energy drink modify the effects of alcohol in a maximal efforts test? *Alcoholism: Clinical & Experimental Research. 28,* 1408-1412.

Fillmore, M, Roach, E, & Rice, J, (2002). Does caffeine counteract alcohol-induced impairment? The ironic effect of expectancy. *Journal of Studies on Alcohol, 63,* 745-754.

Nolan, Joseph N. (2008). Letter to The Honorable Nicole Nason. Petition for Rulemaking: 49 CFR 581Bumper Standard. Insurance Institute for Highway Safety. Retrieved online at: *http://www.iihs.org/laws/petitions/pdf/petition_2008-07-01.pdf.*

Virginia Department of Transportation (2008). *Average Daily Traffic Volumes with Vehicle Classification Data on Interstate, Arterial and Primary Routes.* Richmond, VA.

Virginia State Police (2008). *Police, Crimes and Offenses and Motor Vehicle Laws of Virginia* (p. 404). Charlottesville, VA: Matthew Bender .